

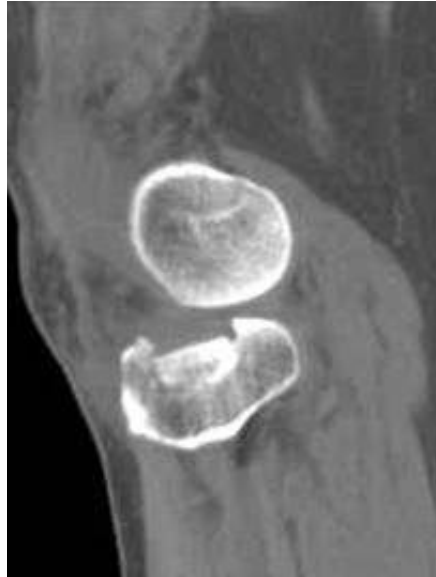Tibial Plateau Fractures

Alan M. Reznik, M.D., MBA

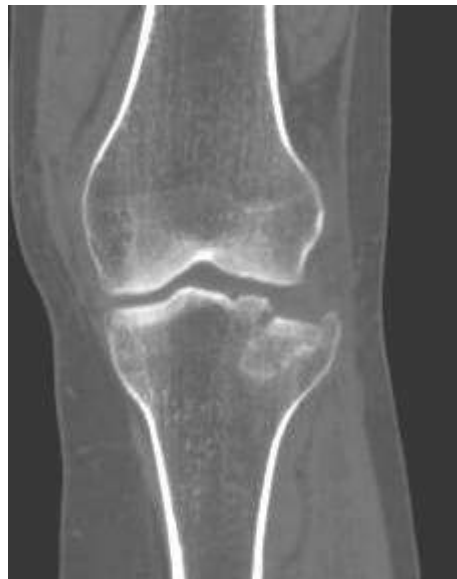The knee has several weight bearing surfaces. The primary loads (weight) in the knee pass from the femur (thighbone) to the tibia (shinbone), with the curved surface of the femur resting on the relatively flat surface of the tibia. Like a mountain with a flat top, this flat surface is called the Tibial Plateau. This is a very sturdy surface, yet it is vulnerable to trauma and can break (fracture). The most common injuries result from a side blow to the knee. This can occur in sports, like skiing and football, or from trauma, like a fall or a car accident. The fracture below occurred when a large dog accidentally knocked its owner over from the side. The stress applied to the outer side of the knee can cause one of two injuries: rupture of the medial ligaments (medial collateral ligament sprain or tear) or collapse of the lateral plateau as seen here. You can imagine how the femur acts as a hammer as it hits the plateau in this type of injury.

There are many types of plateau fractures. These involve the outer (lateral) side, inner (medial) side or both sides (bi-condylar) of the plateau. If the surface is depressed or the sides of the bone are cracked, the plateau can no longer support the femur. This is made even worse if there is a ligament injury associated with the fracture. The unstable knee will be painful, unstable, swollen and often grossly deformed after the injury. The fracture can be detected by checking the medial and lateral stability of the knee, getting plain X-rays and performing CT scans (as in the CT generated image below in Fig 1). When there is instability during the exam or the fracture is significantly depressed (pushed down into the bone), it should be surgically repaired to preserve knee function.

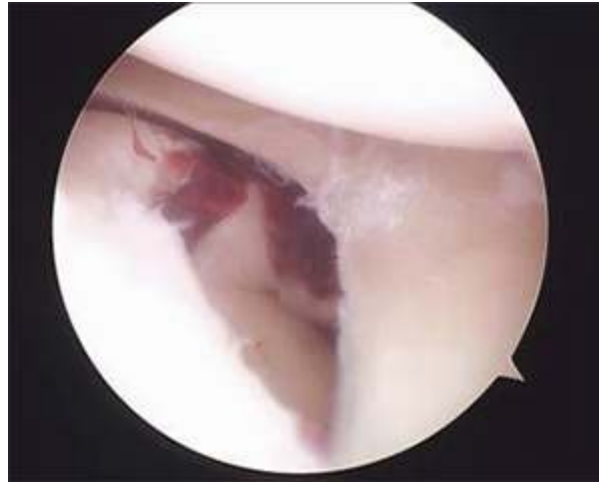A Coronal and Sagittal CT Scan images of a Tibial Plateau Fracture (Below): This reconstructed image (made of many images reformatted by the computer) shows a lateral compression fracture through the lateral tibial plateau. The goal of treatment is to restore the height of the depressed fragment seen here.



Front view of laterally compressed fracture



Side, sagittal, view of the same fracture

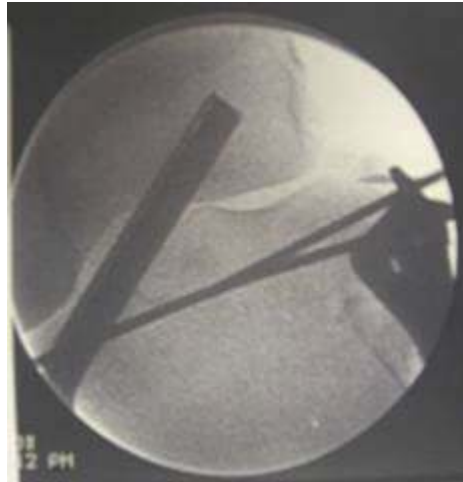

Arthroscopic view of the same fracture

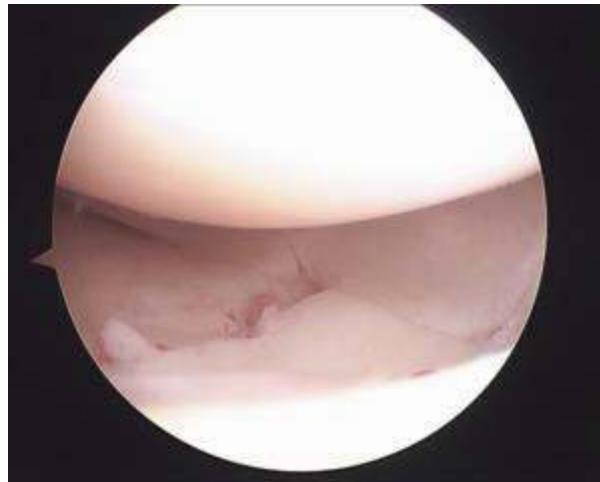
Note how the depressed tibial plateau is no longer supporting the lateral meniscus. This explains the lateral knee instability.

Treatment

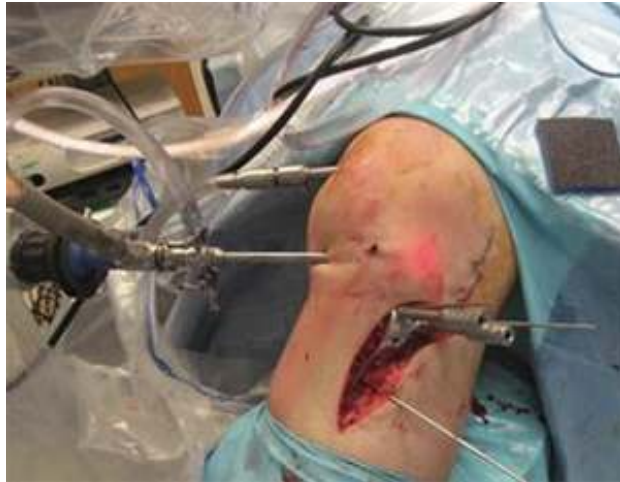Surgery is indicated when the surface is depressed or displaced significantly. Many years ago, up to one centimeter of displacement was accepted for surgery. Now, with CT scans and arthroscopic assisted techniques, no more than $\frac{1}{2}$ a centimeter is accepted and, for some doctors, even less than that. If the plateau is injured and the fracture is depressed, the femur will “fall” into the defect, and the knee will be unstable in the direction of the fracture. Walking on the fracture will worsen the condition. Once the plateau is fractured, the patient should be braced or splinted and placed on crutches. A CT scan is used to “see” the displacement, the number of fractures and the location of the pieces. It can also aid in surgical planning if surgery is necessary. At the time of surgery, an open or arthroscopically assisted method may be used to reduce the fracture and re-align the joint. Bone graft, screws and/or a plate with screws will also be used to support the surface. Newer plates with “locking” screws have improved the strength of these repairs, and precontoured “anatomic” plates have also improved our ability to get a good reduction of the fracture with a better restoration of the normal anatomy. The case below shows the use of a pre-contoured locking plate. Remember that even with a perfect reduction, ideal plate fixation and bone grafting, we cannot undo the crushing injury to the cartilage surface at the time of the fracture. Many of the cartilage cells are killed in the initial blow to the knee, and that cannot be reversed.



Intra-operative X-ray of the scope in place and a trial positioning of the plate with the bone elevated to its normal height.

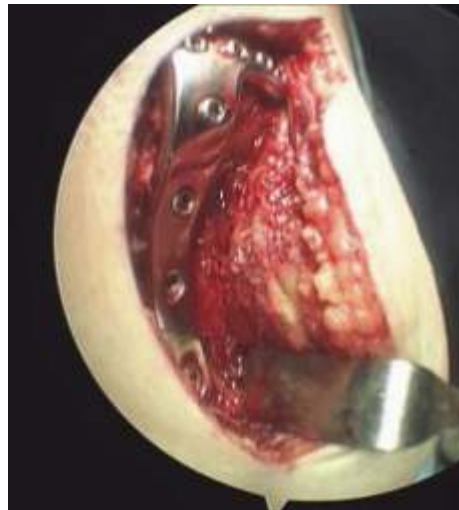

An arthroscopic view of the reduced fracture while the plate and pins are placed. The meniscus is now supported by the bone below.

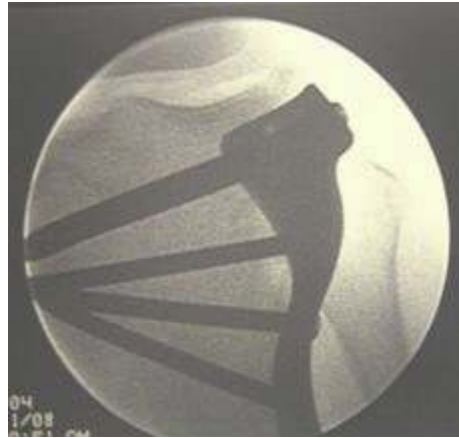

The plate is being placed in position, with the scope inside the knee checking the reduction. The fracture and the plate are being held with temporary pins before the screws are placed.

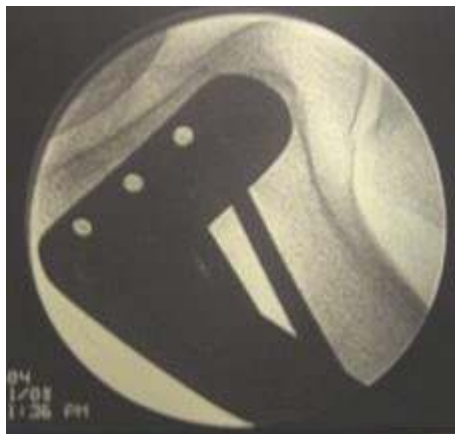Intra-operative fluoroscopic X-rays:



Side view of the plate in place



Final view of the fracture reduced, the bone graft in place and the plate affixed to the bone with the locking screws to fully stabilize the fracture.



This is the final position of the plate in place with eight screws, as seen through the lateral "lazy S" incision. Four screws are holding the tibial plateau surface up; four are fixing the plate to the shaft of the tibia and the medial side of the knee.

Once the fracture is reduced and fixed in place with the plate and screws, the wound is closed, and the patient is placed in a straight knee brace to protect the knee. He or she may not fully weight-bear for at least 6 to 12 weeks post-operatively, depending on the nature of the fracture, depth of the defect, amount of bone graft used and the surgeon's assessment of the quality of the bone fixation.

© 2020 Connecticut Orthopaedics

Not to be reproduced without the express permission of the author