

Clavicle Fractures – Indications for Operative Treatment

Alan M. Reznik, M.D., MBA

Believe it or not, the clavicle is the only true bone connection between the entire arm and the rest of your skeleton. You may wonder how this is possible since your shoulder and arm seem to be directly connected to your body. To understand this better, think of how far your arm and shoulder can move. Think of how you can touch the middle of your back, your toes and the back of your head. Try this yourself and feel your shoulder blade move on your back. Feeling its movement, you can tell it is not attached directly to the chest. It rides both up and down and in and out over the ribs, controlled by an amazing group of muscles.

Now, feel your collarbone (clavicle) as you move. It is attached to the shoulder blade through a small joint near the top outer tip of the blade, just next to where the deltoid muscle (the largest muscle in your shoulder) attaches. If you follow the collarbone with your finger back towards the center of your body, you will find it attaches to the upper part of your sternum. That joint, the sternal-clavicular joint, is the only point where your whole arm attaches to the rest of the skeleton. It's hard to believe! But, because of this single attachment, the arm and shoulder are allowed a good deal of freedom in their movement. Because the shoulder is attached at one point near the middle of the upper chest, to a bone that's shaped like a thin stick, you can touch almost any part of the rest of your body with little difficulty.

Understanding that the shoulder is attached to the body only through the collarbone helps to explain why the clavicle is frequently fractured (broken) when we fall. Its thin, long shape also explains why it fractures with a direct blow, as in a football tackle. Since it is connecting the body and the arm, it can break if the arm is used as protection during a fall. It is also frequently injured during falls off of a bike or motorcycle accidents.

The clavicle typically breaks in the middle. These breaks can be simple (just two pieces with little displacement) or complex (many pieces and/or displaced). They can be closed (not breaking the skin) or open (breaking through the skin). It can also break near either end. When it breaks, the acromioclavicular (AC) joint or supporting ligaments could also be involved. The injury can occur in young children, teenagers and active adults. The location of the fracture, the angulation, the displacement, the skin status and the age of the patient are all important in considering treatment.

Treatment for Clavicle Fractures

In young children, the fracture ends are often close, and there may be a lot of deformity of the bone. In growing children, the bones will heal even with a lot of displacement or angulation. In general, many simple fractures can be treated with a sling until the fracture starts to mend (or as we often say, gets sticky). A lump may appear as it heals. Then some arm movement will be



permitted. When X-rays show good healing, the patient can gradually resume activities. In time, and with proper treatment, the lump of new bone that first appears will remodel itself back to the shape of the smooth bone. When the fracture is more complex or other structures are involved, surgery can be necessary.

Indications for Operative Treatment of Clavicle Fractures

In general, clavicle fractures in children are treated in a sling. However, there are exceptions: fractures that break through the skin (open fractures), fractures that threaten to break the skin by the nature of their sharp bone ends and how much they tent the skin, fractures with muscles trapped between the bone ends and fractures that cause nerve compression. If any of the above is true, the fracture should be surgically repaired. The same is true in adults except adults heal more slowly and less reliably. Also, in children, the fracture “remodels” as the child grows so the deformity we can expect to heal and remodel back to the normal clavicle shape increases with decreasing age. In other words, the younger the child the more deformity we can accept for an excellent outcome.

There are a few additional considerations for adult patients. One significant factor is the shortening of the fracture. “Shortening” means that the bone is overlapped more than 2cm or is 2cm shorter than normal. In those cases, it should be fixed. Other doctors would add that if it is angulated more than 45 degrees, and, if the shortening is in the dominant arm or in a throwing athlete, no more than 1 cm of shortening can be accepted. In any case, patients with deformity, muscle trapped between the fragments or the other factors noted already also require an open reduction and internal fixation.

Fractures near the acromioclavicular (AC) joint or the outer end of the clavicle may require special care. The fractures that are lateral (away from the neck) to the coracoclavicular ligaments seem to heal well if the ligaments are intact. If the ligaments are torn or the fracture is medial (closer to the neck) to at least one of the two coraco-clavicular alignments, there is a high rate of non-healing (or non-union). These need to be fixed, and if the lateral fragment is small, the challenge is to hold them in place until they heal. Some of these fragments are small and involve the AC joint. When that occurs and the ligaments are torn, removing the fragments and reconstructing the ligaments may be the only viable choice. Newer plates were invented in an effort to solve this complex problem with better results. Once the fracture heals, this special plate may be removed. The distal (most lateral) fractures in children may be growth plate injuries and also need to be fixed.

Fractures of the mid-third of the clavicle do well with non-operative treatment, except for those in which the fracture is displaced posteriorly. That type of fracture can place pressure on major blood vessels and nerves that are just behind the clavicle in this location. In those cases, an open reduction and fixation are needed.

Surgical Fixation of a Displaced Fracture of the Clavicle

The photos are presented here are of a surgery performed by Dr. Reznik with the explicit permission of Dr. Reznik's patient. They are for education purposes only.

(Warning: these are real photos from an actual surgical procedure performed by Dr. Reznik. Do not view if you are averse to seeing surgery photos of a live patient!)

The images cannot be reproduced or modified for any use without specific written permission in advance. All rights are reserved.

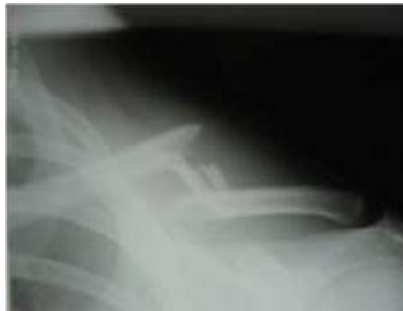

Figure 1: Comminuted fracture of the left clavicle

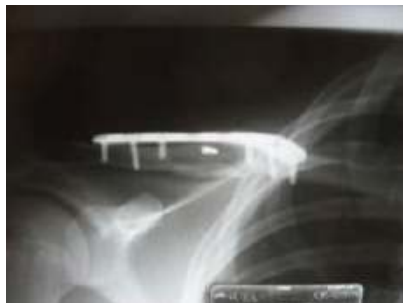

Figure 2: X-ray of a right clavicle fracture reduced with plate

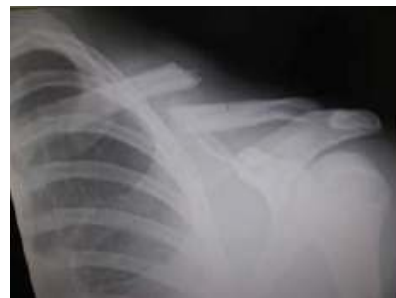

Figure 3: Simple right clavicle fracture with shortening

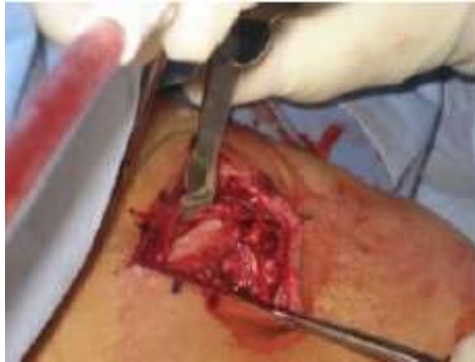

Figure 4: Surgical Approach

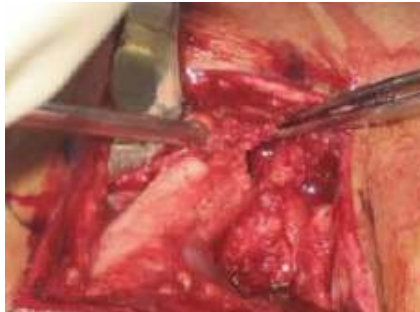


Figure 5: Medial fracture fragment

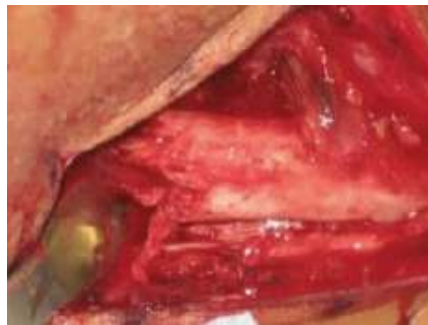

Figure 6: Lateral fracture fragment

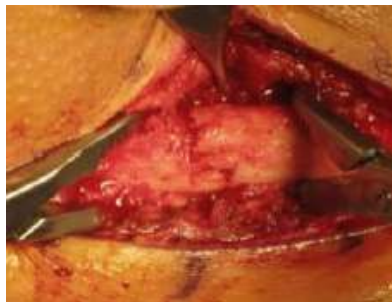


Figure 7: Fracture reduced

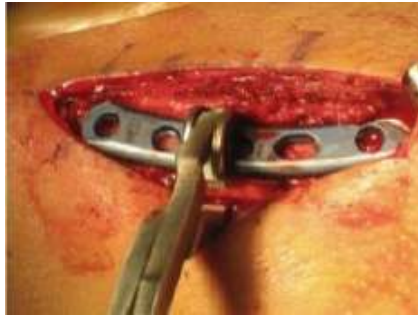

Figure 8: Plate in position

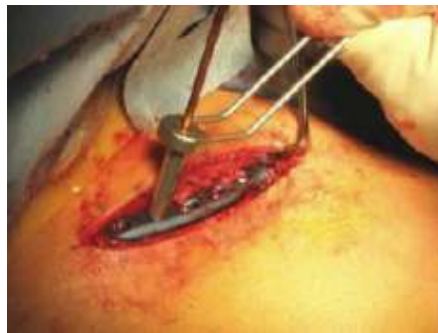

Figure 9: Holes being drilled

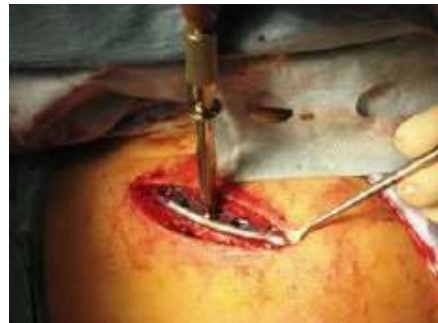

Figure 10: Screws being placed

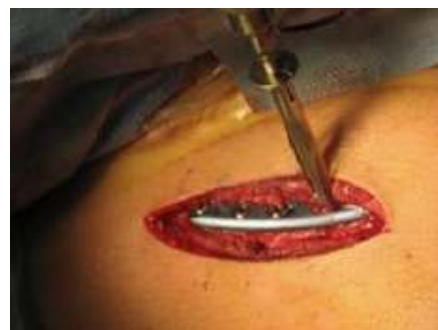

Figure 11: Screws being placed

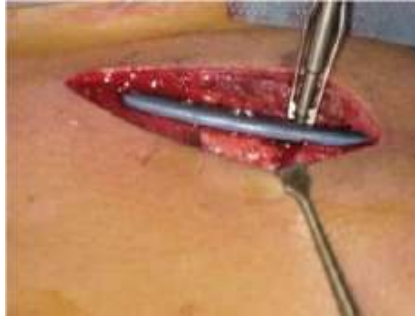

Figure 12: Tightening screws

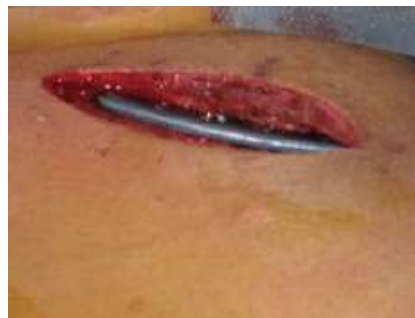

Figure 13: Plate in place with screws

After the repair most patients are much more comfortable than before the broken bones are stabilized by the plate. A sling is used for to protect the arm after the surgery and although the bone is held in place by the plate the bone does not heal for some time. You can start to use the hand for simple activities but not for lifting, pushing (sorry no pushups) or pulling for 3-4 months.

Copyright © 2020, AMReznik All rights reserved. Revised 3/7/11