

Limb Lengthening

Peter A. DeLuca, M.D.

Using technology and an understanding of bone and soft tissue biology that has been gained over the past 75 years, it is now a common procedure to lengthen arms and legs.

The most frequent conditions treated include:

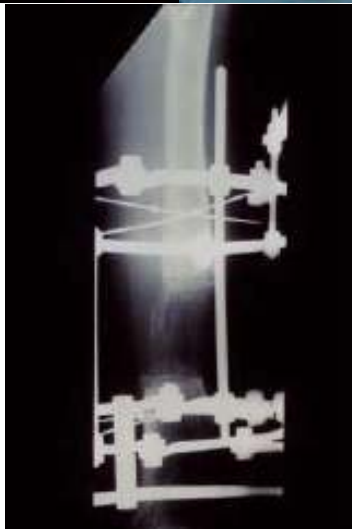
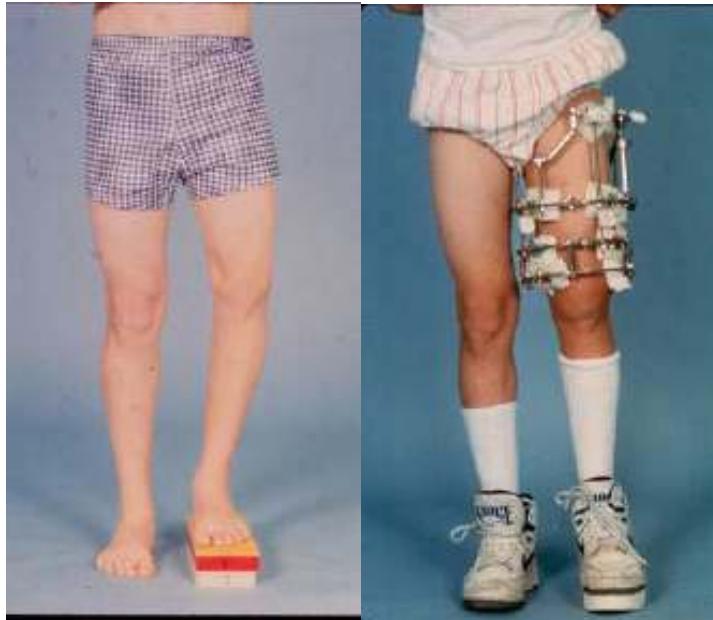
- Congenital limb shortening
 - Tibial or fibular hemimelia
 - Congenital Short femur
 - PFFD (proximal femoral focal deficiency)
 - Idiopathic leg length inequality
- Post traumatic, post infection growth arrests
- Developmental angular deformities
 - Blount's disease
 - Ricketts
- Foot deformities
- Joint contractures

Most surgeons, including myself, who perform such surgery have been trained in the principles of Professor Ilizarov, initially using his methods, but more recently advanced with the techniques and methods of Dr. Taylor. Most corrections are now performed using the Taylor Spatial frame. Uniplane external fixators are also utilized.

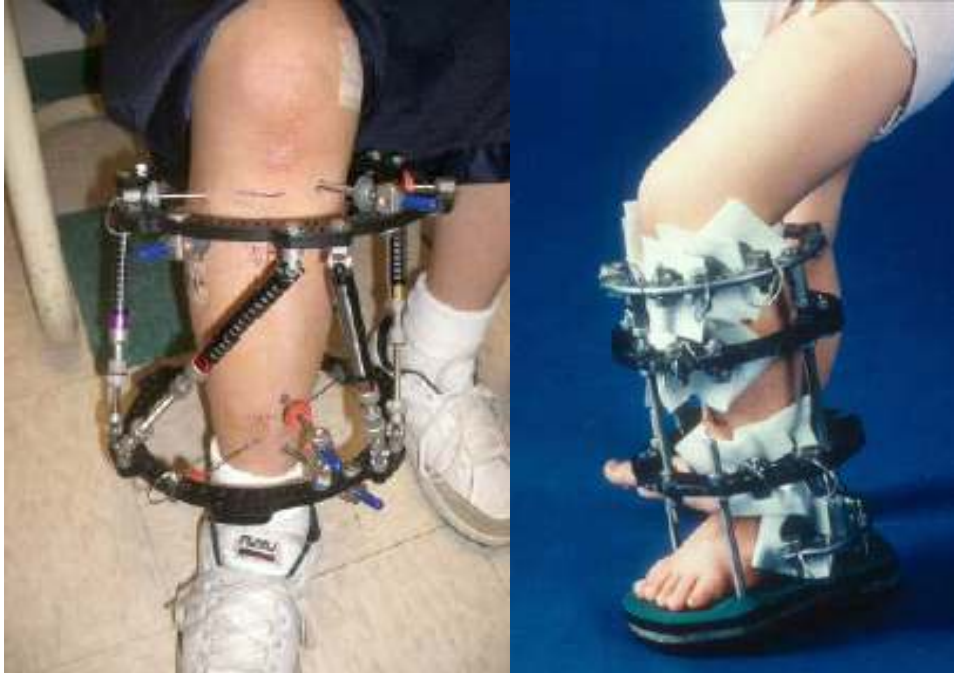At a surgery, an external frame (Ilizarov, Spatial Frame, Monorail, etc.) is applied to the bone to be lengthened or corrected by means of small wires or half-pins. Once the frame is secured, the bone is carefully cut. Approximately a week following surgery, correction is begun, with the patient or family turning small dials, producing 1 millimeter of length per day. It generally takes one month to gain each inch of length, but two additional months for each inch to harden enough to remove the lengthener.

Every lengthening carries with it risks. Usually these are small complications, such as pin infections, which do not jeopardize successful outcome. However, more significant complications can occur.

Femoral Lengthening:

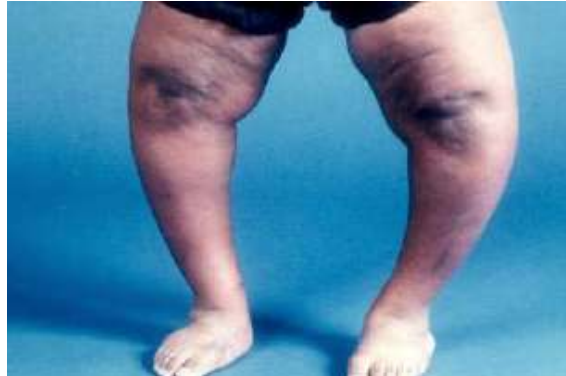


Tibial Lengthening:



Correction of Blount's Disease

Severe Case:



Example of Taylor Spatial Frame:

