

Acromioclavicular Joint (AC Joint)

Alan M. Reznik, M.D., MBA

The photos are presented here with the explicit permission of Dr. Reznik's patient, for education purposes only. The images cannot be reproduced or modified for any use without specific written permission in advance. All rights reserved.

(Warning: These are real photos from an actual surgical procedure performed by Dr. Reznik. Do not view if you are averse to seeing surgery photos of a live patient!)

Figure 1: Shoulder Strap Incision - this is used because of the ability to extend the exposure if needed. It lies in the natural lines of the skin, making it a more cosmetic incision than would a transverse incision in this same location.

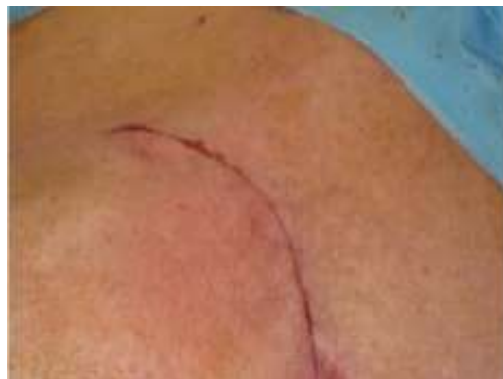

Figure 2: Developing the next layer the muscle/fascia plane of the deltoid and trapezius muscles.

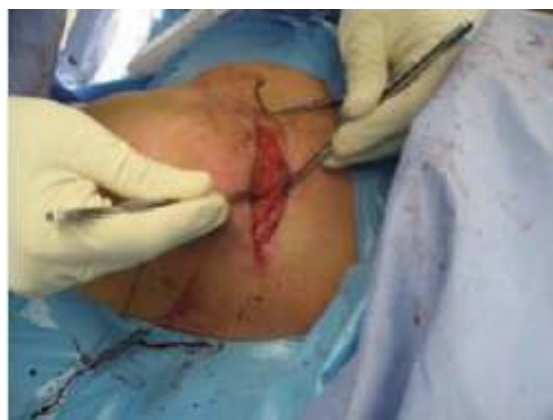

Figure 3: Exposing the clavicle (collar bone).

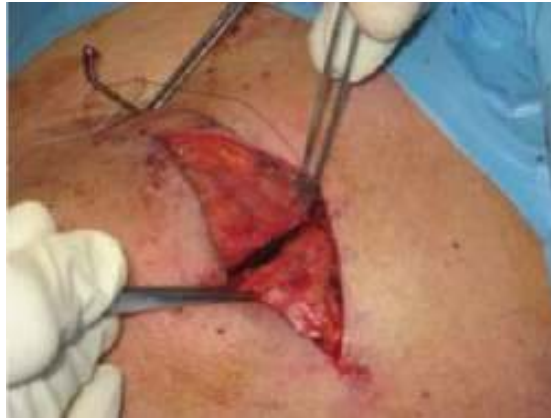

Figure 4: Seeing the edge of the unstable bone.

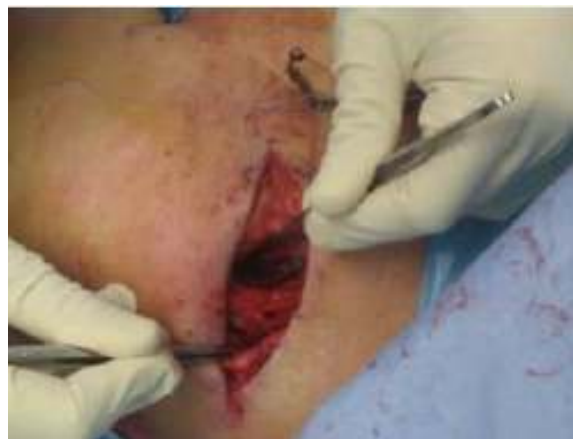

Figure 5: The holes have been drilled in the distal collar bone for the placement of the tendon graft after replacing the acromioclavicular ligaments in their natural position around the coracoid process (not seen here) of the scapula (shoulder blade).

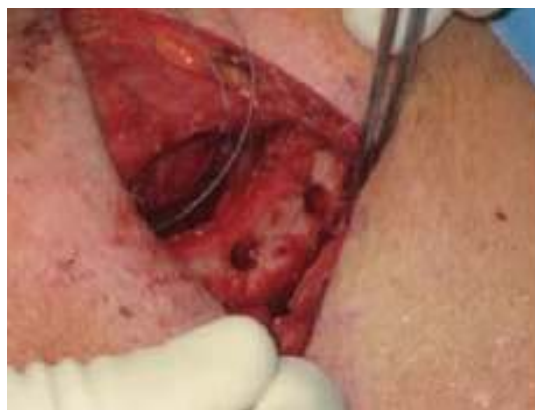

Figure 6: A special clamp, the Stedinsky Clamp (often used in open heart surgery) is used to pass the sutures around the coracoid process. These sutures aid in passing the actual tendon graft that has been prepared separately on the OR table for graft placement later in the procedure.

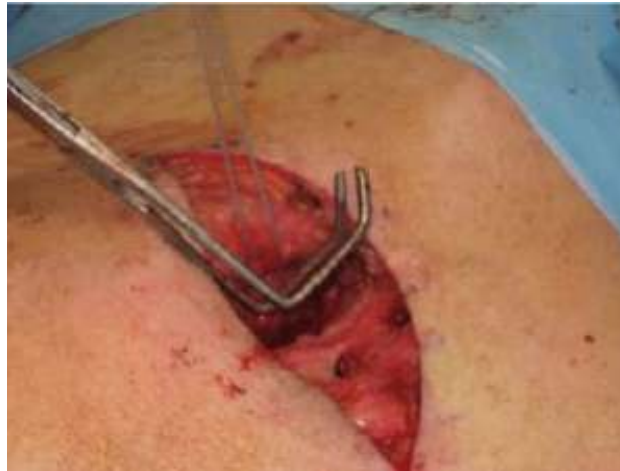

Figure 7: The guide sutures are passed prior to passing the graft.

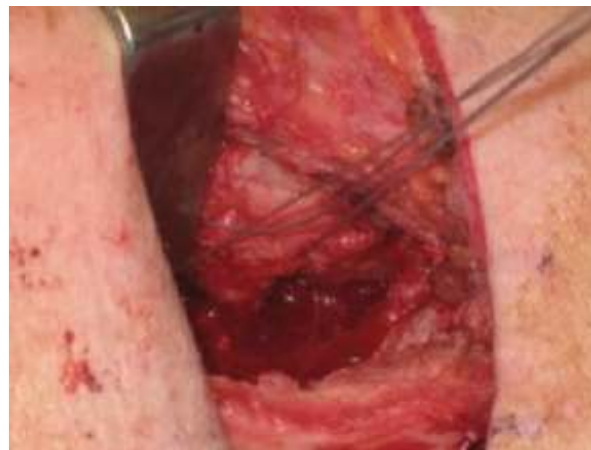

Figure 8: The suture loops that are attached to the leading ends of the graft are passed through the guide sutures.

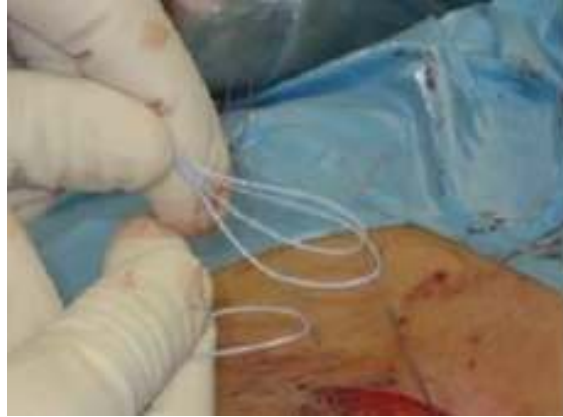

Figure 9: These loops are then passed under the coracoid process.

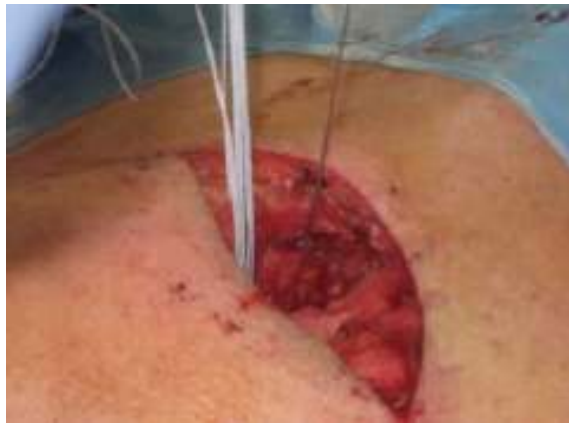

Figure 10: The graft follows the loops under the tip of the coracoid process.

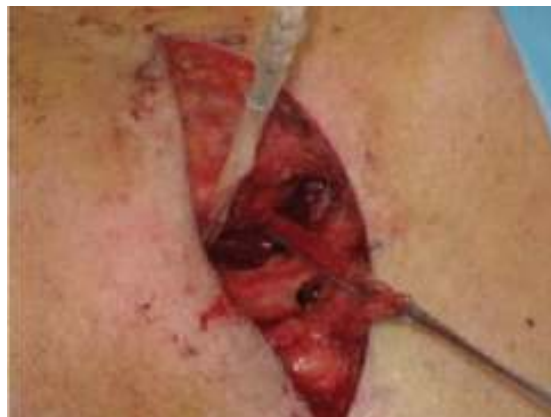

Figure 11: The graft is passed through the pre-drilled holes in the collar bone.

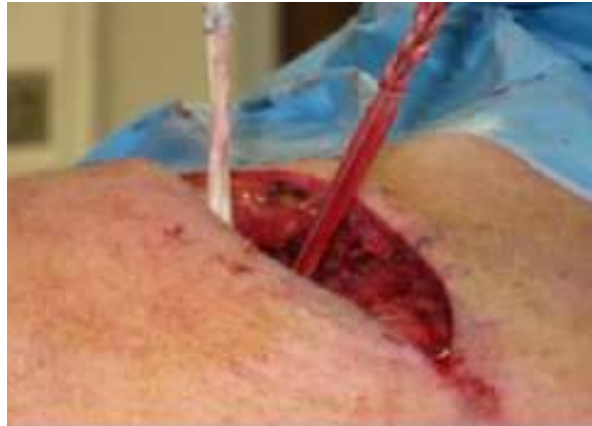

Figure 12: The graft is fixed in place with special screws with mechanical properties similar to natural bone.

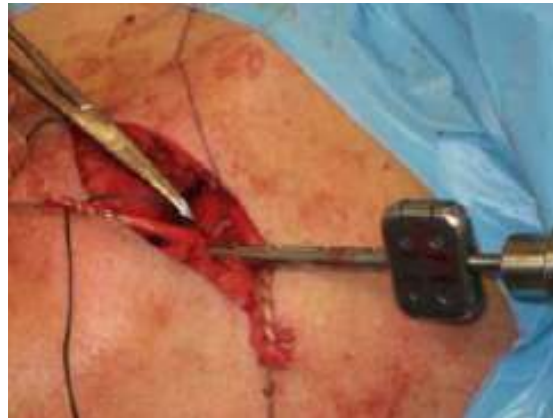

Figure 13: The screw is seated flush to bone.

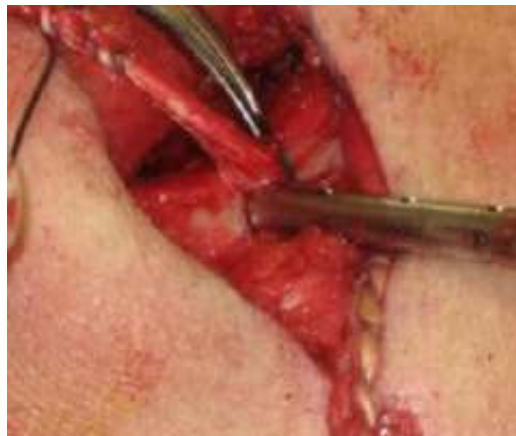

Figure 14: Once the coraco-clavicular ligament grafts are set and secure, the graft ends are tensioned and pulled laterally to repair the ligaments between the acromion and the clavicle.

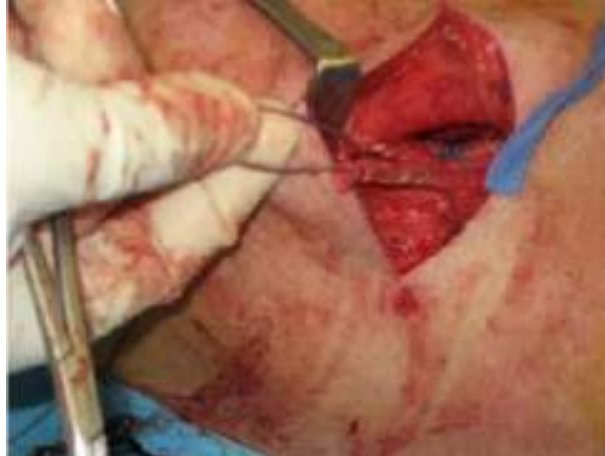

Figure 15: Close up of the grafts passing out of the drill holes.

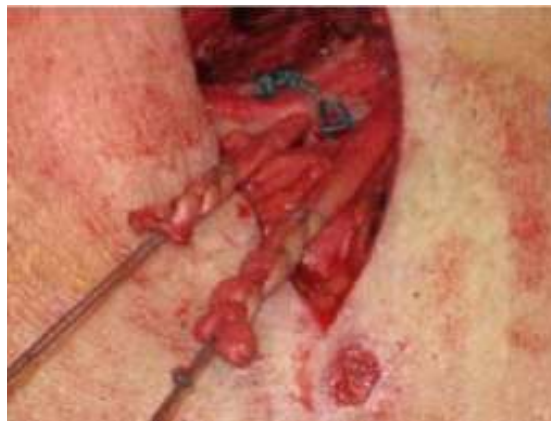

Figure 16: Positioned toward the AC joint.

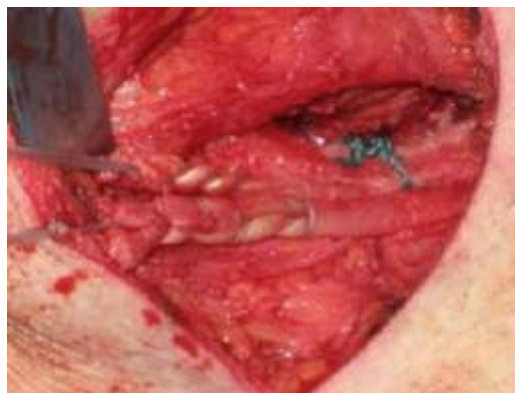


Figure 17: Graft limbs secured to the acromion.

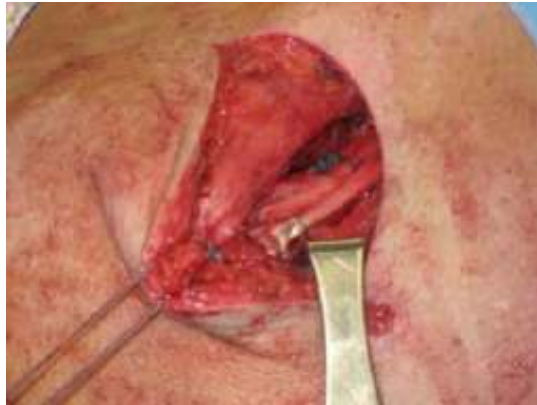

Figure 17A: Close up of complete four ligament repair.

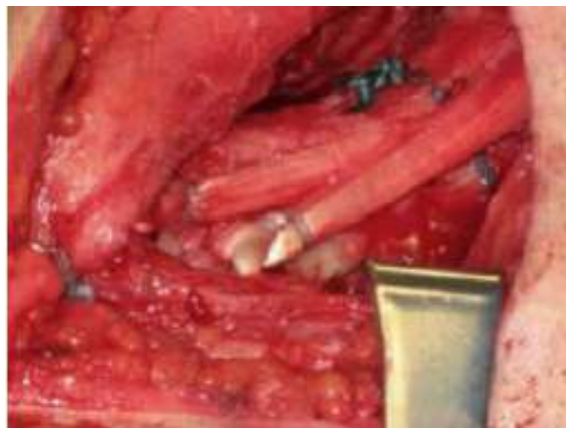

Figure 18: Closure: Deltoid- Trapezius Muscle repair.

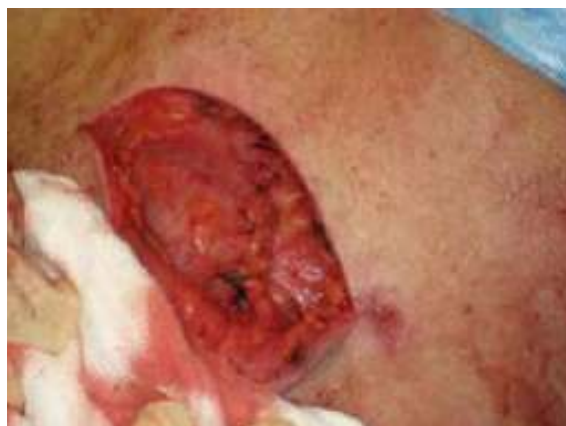

Figure 19: Skin closure, repair completed.

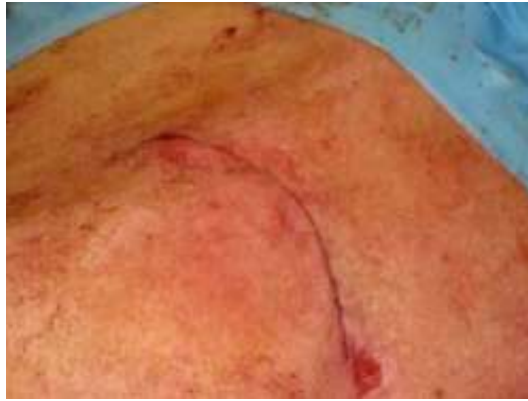
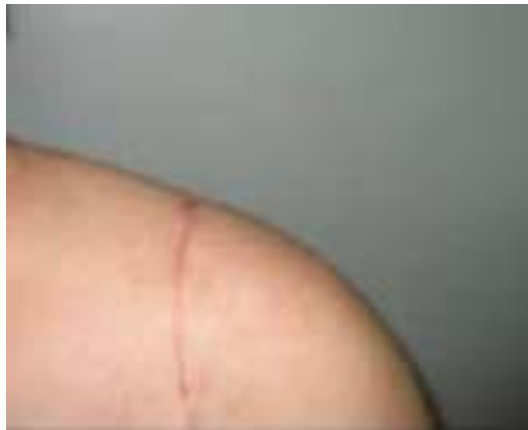

Figure 20: Healed incision for the repair.



Copyright © 2020, AMReznik All rights reserved. Revised 3/7/11