

## Rotator Cuff Tears and Repairs

By: Derek S. Shia, M.D.

Rotator cuff tears are one of the most common orthopedic problems and affect more than 17 million persons annually in the United States. The rotator cuff is an essential group of four muscles that control shoulder motion and contribute to the concentric reduction of the glenohumeral joint. Rotator cuff tears have a tremendous effect on a patient's ability to perform athletic activities such as tennis, golf, and softball but can also affect simple activities of daily living such as sleeping, brushing teeth, and combing hair. Not all rotator cuff tears occur due to a traumatic incident and many patients may be living with a painful shoulder as a result of a rotator cuff tear without knowing it. There are various treatment options available to patients depending on their age, activity level, size of tear and the length of time that the tear has been present.

### Patient Presentation

There are two principle populations that are affected by rotator cuff tears. The first is young patients that have experienced a significant traumatic event that causes the rotator cuff to tear. The event that causes this is usually a high energy injury and patients complain of an immediate change in their ability to use their arm. The second group of patients is an older population that typically cannot recall a traumatic event. These patients often have an insidious onset of shoulder pain and weakness. They complain of an inability to perform activities above shoulder height such as washing their hair or lifting dishes up to high shelves as well as pain reaching behind themselves. Night pain is also very common, and patients commonly seek treatment because they have a difficult time sleeping.

While these two groups make up the majority of patients there is certainly an overlap between these patient groups. Patients that need to be closely evaluated include patients over the age of 45 with a shoulder dislocation as well as patients who fall without radiographic evidence of a fracture but with weakness.

### Prevalence of Rotator Cuff Tears

The incidence of rotator cuff tears is very strongly correlated with a patient's age. Several studies have been recently published investigating this relationship. One of these studies utilized ultrasound to determine the prevalence of rotator cuff tears in 237 asymptomatic individuals. They found that age was strongly correlated with the prevalence of a full thickness rotator cuff tear. None of the patients age 40-49 demonstrated rotator cuff tears, patients who were age 50-59 demonstrated a 10% prevalence of a full thickness rotator cuff tear, patients age 60-69 demonstrated a 20% prevalence and patients older than 70 had a 41% prevalence of a full thickness tear. The importance of this study demonstrated the relationship between age

and the likelihood of the presence of a full thickness rotator cuff tear in patients with no complaints of shoulder pain or weakness. In a related study 588 patients who had unilateral shoulder pain had the opposite shoulder examined with ultrasound. This study demonstrated a high incidence of rotator cuff tears in older individuals with 50% of patients over the age of 65 demonstrating a full thickness rotator cuff tear in the opposite shoulder that was asymptomatic.

## Natural History of Rotator Cuff Tears

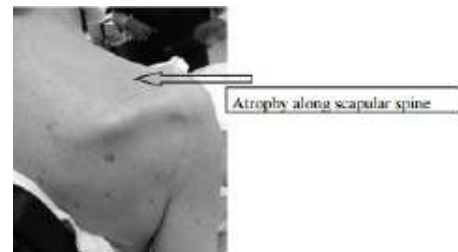
It is important to consider the specific patient in terms of their functional status and also the natural history of untreated rotator cuff tears when contemplating various treatment options. Unfortunately, there is no evidence that rotator cuff tears can spontaneously heal without surgical intervention but depending on the patient and the size of the tear it is possible to make a rotator cuff tear asymptomatic. In a recent study investigating the natural history of non-surgically treated rotator cuff tears that were followed for 5 years, no tears showed any evidence of healing. Of the patients that became symptomatic again after a trial of non-operative management 50% of those patients had an enlargement of the tear. Of the patients that remained asymptomatic over the 5 year period, 20% had an enlargement of their tear. Of the patients whose tear increased, the average increase in size of the tear was 30%.

When considering that rotator cuff tears do not heal without surgical intervention it is important to think about the implications for the patient. When a rotator cuff tear does occur, irreversible changes of the muscle can begin within the first three months after an injury. Without the proper length/tension relationship fatty infiltration will begin in torn rotator cuff muscles. This process results in the replacement of the normal muscle tissue with fat, causing a permanent change in the elastic properties of the muscle tendon unit. This change is irreversible and can affect both a patients' outcome after surgery and result in a rotator cuff being irreparable at the time of surgery. Various studies have investigated fatty infiltration after a rotator cuff repair and they have found these changes do not reverse even after repair of the tendon.

## Physical Exam

The physical exam is one of the most important parts of the patient evaluation and is instrumental in obtaining the correct diagnosis. Inspection of the shoulder should include evaluation of any atrophy along the scapular spine which is often indicative of a chronic rotator cuff tear.

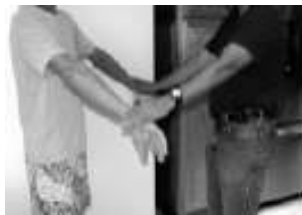Evaluation of a patients shoulder range of motion is vitally important in determining the correct diagnosis. Shoulder motion comes both from the glenohumeral joint which is responsible for 2/3 of the overall motion and the scapulothoracic joint which is responsible for the remaining 1/3 of overall shoulder motion. It is important to separate these two motions to detect pathology in the shoulder joint.



Scapular kinematics are often abnormal following rotator cuff injuries and can be seen when evaluating the scapula during shoulder range of motion. The assessment of active and passive range of motion is also critical. Loss of both active and passive range of motion is often indicative of an adhesive capsulitis while loss of only active range of motion is often suggestive of rotator cuff pathology.

While there are a multitude of described tests for evaluation of the rotator cuff, I have included some of the most common and helpful ones for detecting rotator cuff pathology.

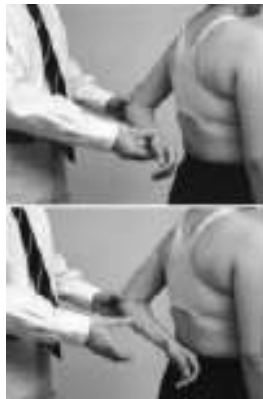The empty can test helps to evaluate the supraspinatus, the most commonly involved muscle in rotator cuff pathology.



Test of external rotation strength with the shoulders in internal rotation will help evaluate the infraspinatus.



The lift off test will help evaluate the function of the subscapularis.



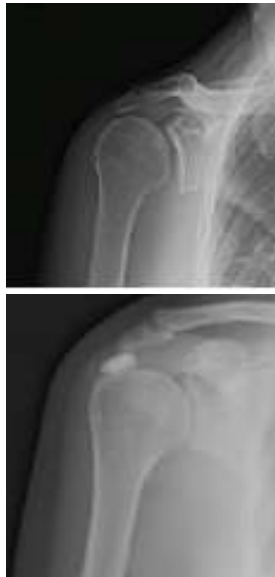The horn blower test will help evaluate the teres minor and is often only positive in massive rotator cuff tears.



Evidence of massive rotator cuff tears include a positive drop arm sign, which is the inability for a patient to hold their shoulder in external rotation, a positive horn blower test, as well as a pseudoparalysis of the shoulder when a patient is unable to actively lift their shoulder to 90 degrees.

## Imaging

Radiographs are an important modality when examining pathology around the shoulder and can suggest rotator cuff pathology. This x-ray demonstrates chronic rounding of the greater tuberosity often seen in long standing rotator cuff tears. It also demonstrates superior translation of the humeral head relative to the glenoid and gapping of the glenohumeral joint. Other pathology that can be appreciated by radiographs include both arthritis and calcific tendonitis which can sometimes present similarly to a rotator cuff tear.



MRI is an integral modality in the evaluation of a rotator cuff tear and adds important information regarding the extent and treatment of the tear. Choices between open and closed MRI's are a common discussion with patients and are often driven by patient choice, body habitus and difficulty with claustrophobia. While open MRI's continue to improve, closed MRI's utilize a



larger magnet and provide a clearer picture of all the involved pathology and improves the ability to make an accurate diagnosis.

An MRI can help determine the size of the tear and which tendons are involved, it can demonstrate the amount of retraction of the tendon and the amount of fatty infiltration. All these factors are important for determining the likelihood that a tear is repairable and whether it will heal.

## **Treatment Options**

There are various non-operative treatment options including activity modification, NSAIDS, physical therapy, and corticosteroid injections. The goal of these treatments is to reduce pain, increase range of motion, and improve function. The goals of physical therapy are to strengthen the remaining rotator cuff, improve scapular kinematics that are often abnormal after a rotator cuff tear, and strengthen scapular stabilizers. Physical therapy also works to improve range of motion and promote functional return to normal activities.

The use of corticosteroid injections for rotator cuff disease is commonly used. The use of corticosteroids has been extensively studied and through multiple studies and meta-analyses have demonstrated limited efficacy in the long-term treatment of rotator cuff disease. One benefit that has been shown is an improvement in pain levels in patients in comparison to placebo over the short term.

There are downsides to repeated corticosteroid injections with a theoretical reduction of overall tendon strength. Basic science research has predominated these studies and have even demonstrated increased type III collagen expression after only a single injection. For this reason, while a single corticosteroid is often considered, multiple injections should be judiciously utilized. Multiple injections over time are often reserved for patients with limited functional goals and inability to undergo surgical intervention.

## **Surgical Intervention**

Surgical intervention for a repairable tear can be treated arthroscopically in the vast majority of cases. The advantages of an arthroscope versus an open repair includes several things including the ability to fully evaluate and treat any additional intra-articular pathology, preserve the deltoid muscle, and allow full access to the shoulder. Controversy continues to exist regarding the optimal surgical construct for the treatment of rotator cuff tears and whether a single or a double row repair best treats the pathology. A double row repair provides a more anatomic reconstruction of the rotator cuff footprint and may lead to lower re-rupture rates in comparison to single row repairs in larger tears. This is currently a hotly debated topic and while basic science studies demonstrate benefits, functional differences have not been demonstrated to be statistically significant between either repair type in clinical studies.



Arthroscopic rotator cuff repair is performed as an outpatient procedure and normally takes between 1- 2 hours depending on the size of the tear and any concomitant pathology that needs to be addressed. The post-operative regimen typically involves a sling for the first 4 weeks. For smaller tears immediate motion is begun and for larger tears there is a period of immobilization. Strengthening is started at 12 weeks with gradual return to normal function. There are very good reported outcomes in the literature following rotator cuff repair with good alleviation of pain and return to functional status.

For certain patients the size and chronicity of their tear may not allow a primary repair. For these patients depending on their age and functional status various treatment options are available. These include tendon transfers including latissimus dorsi and pectoralis major transfers. These are primarily used in younger patients with painful large chronic tears but with good function. The second treatment option is the reverse total shoulder replacement.

This option is reserved for older patients with a chronic irreparable rotator cuff tear and poor shoulder function. This option through a replacement of the shoulder joint eliminates pain and improves shoulder function.

## **Factors that Effect Outcomes After Surgery**

Several factors have been demonstrated in the literature to negatively affect the functional outcome of patients following rotator cuff repair, these include: smoking, diabetes, patient age, the size of the rotator cuff tear , whether the rotator cuff tear is full thickness or partial thickness, and the degree of fatty infiltration. Some of these factors cannot be controlled but early diagnosis and treatment can avoid some of these pitfalls.

## **Treatment Algorithm**

While no treatment algorithm is without exceptions this is a generalized way to think about rotator cuff tears and their treatment. Partial thickness tears have some risk of enlarging but a trial of non-operative management is indicated to see if a patient will do well without surgery. The second class of patients is the young patient who has a full thickness tear or any patient with an acute tear. In this patient population there is more downside to delaying surgery in that the tear will not heal itself, it may enlarge, and that the rotator cuff may undergo irreversible fatty infiltration. In this patient population surgery is indicated. The third category is elderly patients with a chronic rotator cuff tear. This is another population when waiting will have little impact on the patients' outcome and non-operative treatment should be attempted.

## **Summary**

Rotator cuff tears are extremely prevalent and have a significant impact on the patients who have them. A careful physical exam, good imaging and understanding of rotator cuff pathology and its natural history are instrumental in obtaining the correct diagnosis and developing the appropriate treatment course for a patient with a rotator cuff tear. While non-operative



treatments are commonly utilized initially there are many minimally invasive treatment options available if surgery is necessary and good to excellent results are common following intervention.

© 2020 Connecticut Orthopaedics

Not to be reproduced without the express permission of the author